ON DIFFUSE SCLERODERMA; WITH SPECIAL REFERENCE TO DIAGNOSIS, AND TO THE USE OF THE THYROID-GLAND EXTRACT.

BY

WILLIAM OSLER, M.D.,

Professor of Medicine in Johns Hopkins University, and Physician-in-Chief to the Johns Hopkins Hospital.

REPRINTED FROM THE JOURNAL OF CUTANEOUS AND GENITO-URINARY DISEASES, FOR FEBRUARY AND MARCH, 1898.

ILLUSTRATING DR. OSLER'S ARTICLE ON
SCLERODERMA.

[Reprinted from JOURNAL OF CUTANEOUS AND GENITO-URINARY DISEASES, Feb. and Mar., 1898.]

ON DIFFUSE SCLERODERMA; WITH SPECIAL REFERENCE TO DIAGNOSIS, AND TO THE USE OF THE THYROID-GLAND EXTRACT.

BY WILLIAM OSLER, M.D.,
Professor of Medicine in Johns Hopkins University, and Physician-in-Chief to the Johns Hopkins Hospital.

I. GENERAL PICTURE OF DIFFUSE SCLERODERMA. II. SCLERODERMA AND GRAVES' DISEASE. III. DIFFERENTIAL DIAGNOSIS. IV. SCLERODERMA AND ADDISON S DISEASE. V. THE TREATMENT OF SCLERODERMA WITH THYROID EXTRACT.

THOUGH studied and described by neurologists and dermatologists, the diffuse form of scleroderma is perhaps more often seen by the general physician, whom the victim consults for rheumatism or disability. The disease is fortunately rare. I never saw a case until 1891; in 1893 a second case was admitted; in 1895 a very remarkable case was brought to me by Dr. Davis of Saginaw; in 1896 there were four patients with the disease in my wards, and in 1897 another case was admitted. These eight cases, forming the basis of this paper, serve to illustrate a number of points in the symptomatology and diagnosis of this extraordinary affection.

The statistical frequency of the disease in America is given as 0.030 by Hyde. Heller and Lewin give only thirty-two cases reported from North America (out of a total of 451 available for statistics of locality). Of the eight cases one came from Baltimore, three from the State of Maryland, two from Virginia, one from Kansas, and one from Georgia. All were whites.

The monograph of Lewin and Heller[1] covers the whole question so thoroughly that to reporters of cases there is left only the duty of calling attention to special features or unusual complications.

The pathology of the disease is fully discussed in the works on dermatology, and in the monograph referred to. We know really nothing of the essential causes, and the data are not yet at hand upon which a satisfactory theory can be based. The disease is variously regarded as a trophoneurosis dependent upon changes in the nervous system; a perversion of nutrition analogous to myxedema and due to disturbance of the thyroid function; a sclerosis following widespread endarteritis; a primary slow hyperplasia of the collagenous intercellular substance of the corium—fibromatosis; or a primary affection of the lymph-channels, central or peripheral. The first-named view, the one most generally held, may well serve as a working hypothesis.

In order to utilize most fully the material at my disposal I will distribute the cases as they illustrate various points, such as the average clinical picture, the association of scleroderma and Graves' disease, the difficulty in early diagnosis, the recognition of certain cases from Addison's disease, and, lastly, the question of treatment with the thyroid extract.

I. THE GENERAL PICTURE OF DIFFUSE SCLERODERMA.

In its more aggravated forms diffuse scleroderma is one of the most terrible of all human ills. Like Tithonus, to "wither slowly," and like him to be "beaten down and marred and wasted" until one is literally a mummy, encased in an ever-shrinking, slowly contracting skin of steel, is a fate not pictured in any tragedy, ancient or modern. The following cases present the usual features of the disease in its various stages:

CASE I. *Recurring Arthritis before Onset; Diffuse Scleroderma; Sclerodactylism, Trophic Lesions.* (Fig. 1.)—Alice B. of Virginia, aged thirty-nine, admitted October 23, 1893, complaining of stiffness in the joints, and difficulty in movement.

Family History.—Her father died of Bright's disease; her mother of an unknown cause. She has fourteen brothers and sisters. She knows of no hereditary disease in her family.

Personal History.—She has been very healthy; as a child, had measles. She has been married seventeen years, and has had seven children. There has been no disturbance of the menstrual function; she has had no miscarriages. Her youngest child is three years old.

Present Illness.—Seven years ago she had attacks of stiffness with severe

[1] "Die Sclerodermie," Berlin, 1895.

pain in the left knee, which would last from three days to a week. She had to go to bed, and the joint was often hot and sore. Then she would be up and about for five or six weeks, and another attack would prostrate her. After about a year the elbows and the right knee became affected, and would be hot and tender for a few days or for a week at a time. Between the attacks she felt perfectly well. With the arthritis she very frequently had an eruption of red, raised, circular spots, varying in size up to half a dollar; they would appear suddenly, spread rapidly over the body, and slowly fade. The joint attacks lasted for two or three weeks, and were repeated on many occasions. Subsequently the rash occurred without any relation to the articular attacks.

About two years ago the right elbow and wrist became swollen, and after the disappearance of the redness and pain she noticed that the joints

FIG. 1.

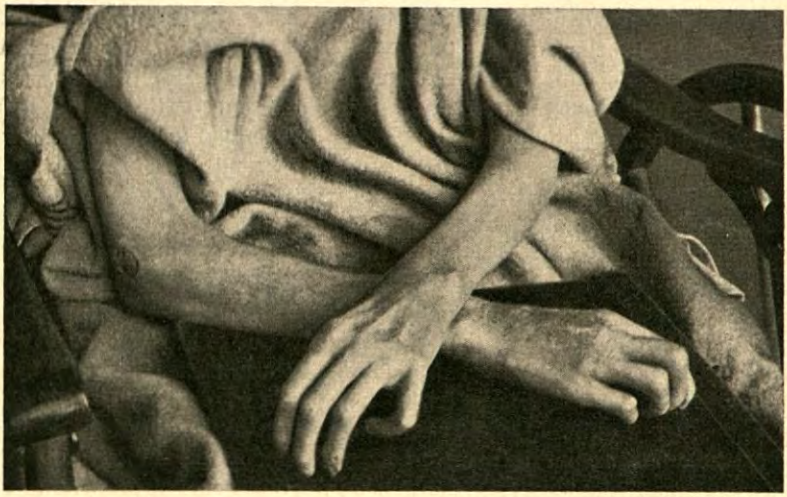

of the index-finger were stiff. Gradually the right wrist, the fingers of the right hand, and the right elbow became stiff, the whole process taking about two years. About two months after the right hand became involved, the left hand was affected, the wrist first. The knees and ankles have only lately been attacked, and she still has good movement in them.

She first noticed the skin of the right hand and arm becoming dry and glossy about two years ago, of the left a little later. She thinks that for several years she has had slight numbness in the arms and legs. The condition is very much worse in winter and in cold weather.

The first open sore developed on the ulnar side of the right wrist eighteen months ago, and remained open for about six weeks. Since then she has had sores on the elbows, finger-joints, and outer side of left ankle. The

sore on the right elbow began three weeks ago. She has noticed wasting of the limbs for about two years, shortly after the stiffness began. Her body, too, is thinner than it was. For a year she thinks she has had a little stiffness in the face, a little difficulty in moving the muscles, and in opening the mouth. There has been very little actual pain. She has not had any skin eruption lately. Her appetite has been very good; she has vomited occasionally, and has had several attacks of cramps in the abdomen lasting from eight to twenty-four hours. She has had no cough. The bowels have been regular.

Present Condition.—Patient is a small-sized, delicate looking woman. The face presents a remarkable appearance. The forehead is smooth, without a trace of wrinkling. The skin has everywhere a drawn, tight look, especially about the mouth, the angles of which are drawn down. There is a marked pallor of the entire face. The eyes can be opened and closed fairly well. The nasolabial folds are present, and there are a few wrinkles at the corners of the mouth. The lips are thin, and the upper one appears to be drawn tightly over the teeth. There is very great restriction of the movement of the lips, and of the muscles of the face. She smiles with great difficulty. The maximum transverse diameter of the mouth is 3.5 cm. The incisor teeth can only be separated about 2 cm. The scalp can be moved slightly; the patient says it is less movable than formerly. Her hair is very thin, and she says that it came out a great deal last winter. The movements of the head are good. The thyroid gland is not enlarged.

Arms.—There is general wasting; the movements at the shoulder-joint are limited; the arms cannot be lifted to the level of the shoulder. The difficulty seems to be more in the skin than in the joints. The forearms are semiflexed, and cannot be extended. Flexion is possible to a limited extent. The limitation in movement seems to be due to the hidebound state of the skin. Everywhere over the shoulders and arms the skin has a smooth, glossy, peculiarly waxy look. The skin can nowhere be pinched up, but is firmly adherent to the tissues beneath. A few hairs are seen on the extensor surfaces of the arms. On the outer surface of the right elbow there is a superficial ulcer, and another on the outer side of the wrist. The movement in both wrist-joints is very limited.

The fingers of both hands are contracted and held in the flexed position of typical claw-hand. There is very slight movement in the metacarpo-phalangeal joints; the little finger of the left hand is flexed at right angles. On the knuckles there are small dry scabs surrounded by hyperemic zones. These, the patient says, may go on to ulcers, or may dry up. There is a small ulcer on the first joint of the little finger of the right hand. The fingers look thin; the skin is drawn, smooth, and glossy, and can nowhere be picked up. In places it has a slight yellowish tint. Over the joints and at the tips of the fingers, which are very much contracted, there is a pinkish tint, which contrasts strikingly with the general waxy pallor of the fingers. The nails are discolored, yellowish, very brittle, and marked with very

rough longitudinal grooves. There is scarcely any movement in the finger-joints. They cannot be extended, nor can she flex them.

Trunk.—The skin over the upper part of the chest is thickened, a little glazed, and is with difficulty picked up. The skin of the abdomen is relaxed and looks natural.

The legs are small; muscles wasted. The skin covering the thighs is drawn tightly, thickened, rough, and closely united to the subcutaneous tissues. This condition is much more marked on the right than on the left side. The skin of the legs is affected in the same way. The skin of the feet is much involved, adherent, glossy, and shows in places the scars of former ulcers. The toes look thin; the skin is very hard and drawn, and has a little bluish-pink color, which gives an appearance suggestive of Raynaud's disease. The patient can walk; the movements in the legs, however, are restricted, especially at the ankle-joints and at the knees. The legs cannot be fully straightened. There does not appear to be any special thickening of the joints themselves, but the skin over them is glossy and hidebound.

There is no increase in the skin pigment. The examination of the abdominal viscera is negative. The heart-sounds are clear. The urine has a specific gravity of 1023, and contains neither sugar nor albumin.

The patient was given warm baths, and the skin oiled with frictions, and the local sores carefully treated. She was then given the thyroid extract, (grs. ii, three times a day). She grew very restive, and at the end of ten days decided to go to her home in Virginia. The thyroid extract did not seem to benefit her, but she did not continue the treatment, or give it a proper trial.

September 6, 1896. Heard to-day that this patient, though at first relieved by her stay at hospital, died about eight months after her return home.

This case illustrates the not uncommon onset with arthritis; the skin rash appears to have been of the nature of an erythema multiforme. She presented the most advanced picture of the disease which we have had at the hospital, and in no other case of our series was the skin involvement so extensive, or the sclerodactylism so marked. The trophic lesions in the form of ulcers and their scars were more numerous than usual.

In the following case, the second in order of extent, the disease has made very little progress during eighteen months in which he has taken the thyroid extract.

CASE II. *Diffuse Scleroderma; Onset with Stiffness and Swelling of Hands and Feet; Possible Arrest under the Use of the Thyroid Extract.*—Levi B., Hagerstown, Md., aged forty-four, came to the hospital March 14, 1896, complaining of stiffness of the hands and joints.

Family History.—His father died of pneumonia; his mother of "catarrh

of the lungs"; one brother is living and well; six brothers and sisters are dead. He knows of no similar disease in the family.

Personal History.—He has always been healthy and strong; no serious illnesses; he never has had lues. He is a farmer, and has worked hard. He has been married twenty-five years; has five living children; one died of spinal meningitis.

Present Illness.—About two years ago he began to get stiff and sore in the joints. In the morning he was so stiff that he could hardly move; through the day, with exertion, it would wear off. At the onset he had no swelling of the joints. He thinks that his hands have been stiff and hard for about a year. Last winter his feet were swollen, and the backs of the hands were also swollen like a cushion. He has never been in bed with the swelling of the joints. Has noticed a little stiffness of the face for nearly a year. He says he cannot stand the winters, as his hands get stiff as sticks. He is evidently very susceptible to cold, as even in the cool mornings in the summer he has to wear an overcoat. He is much more comfortable in the hot weather. In the past year and a half the patient has lost a good deal in weight, formerly weighing 250 pounds, now 186 pounds.

Patient is a large-framed, well-built man. At the first glance there is nothing very noticeable about the face other than a slight acne. On more careful inspection it is seen that the cheeks and forehead are unusually smooth; on the left side there is no trace of a nasolabial fold. The color of the lips is good. The eyes close easily, and can be shut tight. The skin of the forehead can be lifted up and wrinkled. He can move all the muscles of the face and of the mouth. Says it does not now feel as stiff as it did. The skin of the cheeks is firm, stiff, and smooth, and can only be picked up in very large folds. The skin of the forehead is not specially parchment-like. The skin covering the lower jaw is distinctly softer than that of the cheeks; there is no involvement of the skin of the ears; no trophic changes. The mouth can be widely opened. The skin of the neck is not involved, except just in the region over the larynx, at which there is a fold distinctly thickened. The thyroid gland cannot be felt. There is apparently no involvement of the skin covering the thorax. The arms can be raised above the head; the left scarcely so much as the right. The restriction of movement is owing to the induration of the skin covering the shoulders. The mobility of the arms backward is a good deal impaired, so that he cannot take off his coat without help.

The skin over the trunk everywhere looks normal. The skin covering the abdomen feels a little board-like and thick.

Arms.—Over the outer aspect of both arms the skin is decidedly brawny and thick, and to a slight extent on the pectoral folds; there is a decided difference between the skin on these parts and that just beneath the clavicles. The skin of the forearms looks and feels natural to about the lower third. Then it becomes parchment-like, and can scarcely be picked up. He can flex and extend the arms, but they feel stiff; pronation and supination can be well performed. The hands and fingers are extensively involved.

They look a little brown, and he says at times they have been almost black. They become readily congested when held down. They are cold, moist, and feel everywhere board-like and firm. The skin of the backs of the hands is much indurated, and on the palms of the hands it is also very firm and hard. The fingers feel like marble. There is no place on any one of them at which the skin can be picked up in the slightest degree. They are semiflexed; he cannot make a fist, and the pads of the fingers cannot be made to touch any portion of the palm of the hand. The fingers are movable only at the metacarpal joints. They are completely fixed at the phalangeal joints. The skin of the back of the fingers looks roughened like shagreen. On the first joint of the little finger there is a scar of a sore. On the pads of the middle, ring, and little fingers of the left hand, and on the ring- and index-fingers of the right there are scars of ulcers, which were present last winter. The nails are not altered, and not at all brittle.

The skin of the legs and feet is not affected. He has a little numbness and tingling in them, but no vasomotor changes. The knee-jerks are normal.

The thyroid gland can be felt, and seems of normal size. There are no changes in the organs of the thorax or abdomen. The pulse is not rapid; the superfiicial arteries are not sclerotic.

The urine was normal. Dr. Barker tested carefully the sensation in the affected areas and found it a little dulled, but without qualitative changes.

The patient remained in hospital for two weeks. He was given the thyroid extract, beginning with 3 grains in the day, and gradually increasing. He was seen again on the 8th of May, when he had been taking the thyroid tablets regularly, since increased to one 5-grain tablet three times a day. There did not appear to be any essential change in the sclerosis, though he thought he was better in some ways.

June 20th. Patient came to-day, and reports that he has been feeling better; less stiffness. To superficial examination there is no special change. October 10, 1896. I saw this patient to-day, and he presented no special change. He thinks, however, that the thyroid extract has benefited him in some ways. He says he moves the arms more freely, and his hands are less stiff. His general health keeps good. The accompanying skiagram of the hand shows very well the absence of any involvement of the bones, and illustrates also the marked contraction of the little finger. (Fig. 2.)

January 9, 1897. Patient came to hospital to-day, and though he expresses himself as feeling better, I can see no special change. It is quite evident that from the date of his first visit in March there has been a progress in the disease. The hands are less freely movable, and he does not lift the arms above the head so readily. He has great difficulty in taking off and putting on his coat.

April 22, 1897. There is no very essential change. The hands are a little congested; he can get the hands up to the head. There is no special change in the skin of the face. The skin of forehead looks pretty natural; that of cheeks is smooth and feels stiff. He has been taking the thyroid ex-

tract steadily since March 23, 1896. There is a little necrosis on the top of the second joint of the little finger, and on the terminal joint of the ring-finger of the left hand. There is little or no mobility in the fingers themselves. They can be moved at the metacarpal joint. The backs of the hands are a little softer. He has gained in weight within the past year, since taking the thyroid extract. He weighed last spring 182, now 204.

November 18, 1897. Patient came to the hospital again to-day. He has continued to use the thyroid extract, omitting it occasionally for a week. He states that he is very much better, but there are no essential changes either in the hands or in the face. If anything, perhaps the fingers are a

FIG. 2.

little less mobile. His general health keeps good, and there certainly has been no extension in the past six months.

We have followed this case with a great deal of interest. He has been most faithful in taking the medicine, and in carrying out our directions. While he insists that he is better and can do more for himself, it is evident that the condition now is not much changed from that of March, 1896.

The third case illustrates extreme scleroderma, with very painful onset. There was a degree of disability out of proportion to the extent of skin involved. The legs showed the erythema and brawny infiltrations of the early stages of the disease. She did not take the thyroid extract long enough to test its efficacy.

CASE III. *Pains in the Joints at Onset; Diffuse Scleroderma of Arms, Hands, and Shoulders; Erythema of Skin over Knees; Brawny Edema of Legs; Pigmentation of Skin of Arms; Death with Gastro-intestinal Symptoms.*—Mrs. Barbara S., aged forty, applied at the Johns Hopkins Hospital, June 24, 1896, complaining of pain and inability to use her arms and legs.

Family History.—Her father died of erysipelas, aged sixty-three; her mother died of pneumonia, aged fifty-nine; one brother is living; one brother died of Bright's disease; there is no history of rheumatism or of tuberculosis in the family.

The patient had the usual diseases of childhood. She is married, and has had eight children, seven of whom are living, She has always been a very healthy woman. She has done a great deal of out-door, and also of indoor, work. She worked very hard all summer and until October (1895). Last summer she had occasional pains in the knees.

The *present illness* came on in October with pains in different joints; the knees, the elbows, and the hands were stiff. The legs were not swollen at first, and she does not remember when they began to swell. There has been gradual impairment of the freedom with which she uses the hands. At first the right, and then the left became affected. She has no actual pain in them, but often an uncomfortable sensation enough to keep her awake. The stiffness has been increasing very much of late.

She was a very dull-witted woman, and she could not say whether her arms and hands had changed much in color, but her friend who came with her, and who lives in town, said that she thought she had changed a great deal, particularly in the arms and hands.

Present Condition.—She is a dark-complexioned woman, with dark eyes; she looks perhaps a little pale and sallow. Her friend says that she has changed much in color, and has become distinctly brownish. There is no change in the condition of the skin of the face, and no trace of any scleroderma; the wrinkles are well marked. The skin of the hands and arms is very much discolored, as dark as the darkest grade of sunburn. No areas of leucoderma. The hands are held in the characteristic attitude, with the fingers semiflexed. She says that she thinks it would kill her to straighten the hands, it is so painful across the joints. To the touch the arms and hands are cold and moist. The fingers cannot be extended at all; they cannot be flexed so that the tips of the fingers come beyond the bases of the metacarpal bones. There is a very great degree of disability. To the touch the fingers are uniformly firm; the skin is moved with difficulty, cannot be picked up on the back of the hand or on the back of the wrists. Over the fingers it is very much hidebound. The pads of the fingers and the skin of the palms of the hands are not so much affected. There is no necrosis. She cannot straighten the arms at the elbows on account of the stiffness of the skin. The shoulders are much affected. She cannot lift the arm above the level of the shoulder. There does not appear to be any special impairment in the movement of the joint itself. The legs are not pigmented. There is marked erythema of the skin over both knees. They are not sore to the touch, but very sore when she walks and when she moves about. The erythema over the joints is very marked, but there is no scleroderma. The legs are swollen; there is a brawny pitting, particularly between the ankles and the knees. The skin of the feet is much congested; there is no actual scleroderma. The skin of the upper arms is not so much pigmented.

The skin over the pectoral fold and over the upper part of the breast, and over the manubrium, is quite hidebound. The thyroid gland cannot be felt. Pigmentation over the chest is very slight.

I heard of this patient through her friends to-day, January 21, 1897. They state that when she came to stay with them in June, 1896, she could not dress or undress herself, and could scarcely get up-stairs. Under the use of the thyroid extract she improved a great deal, so they state. She returned to her home in the country, and from what I can gather must have died of an acute gastro-intestinal trouble. She became worse and more helpless, had nausea, vomiting, and diarrhea, and gradually sank and died.

In the following case scleroderma developed rapidly in the course of ordinary phthisis, possibly without any special relation to the lung affection. In four cases mentioned by Lewin and Heller tuberculosis of the lungs was the cause of death; in one case the scleroderma developed in the subject of long-standing phthisis.

CASE IV. *Pulmonary Tuberculosis; Scleroderma of Skin of Back of Neck and Upper Part of Back, of Chest, and of Upper Part of Abdomen.*—Martin M., aged twenty-nine, was admited to Ward F, May 27, 1891, with tuberculosis of the left apex, and all the accompanying features of that condition in an active state. The lung symptoms had developed within the past six months. Three weeks ago he first noticed a tightness about the neck and back, and a difficulty in moving the head freely. With it there had been some uneasy sensations.

The examination showed a moderately emaciated man. There was nothing special noticed about his face, the skin of which looked and felt natural, except on the lower part of the right cheek, where he says it feels thicker, and it did feel somewhat leathery to the touch. The skin of the scalp is not affected, except behind, over the occipatal protuberance. From this point, extending over the entire back and sides of the neck, the skin is brawny, firm, somewhat whitish in color, and can nowhere be picked up in a fold. The induration extends over the scapulæ and the folds of the trapezii, but the skin in the intercostal regions and over the rest of the back is not at all affected. The induration extends over the shoulders to the outer aspect of the arms over the deltoids. The skin of the front of the chest is everywhere involved, firm, and board-like; the edges of the pectoral folds and the skin of the axillæ are not sclerotic. In front the induration extends over the epigastric region, very slight in the umbilical, and is not present in the flanks and lower zone. The legs are not affected.

The color of the skin is everywhere normal; there are no vasomotor changes; no mottling. On deep pressure it does not pit, but feels thick and board-like. The induration over the trapezius and deltoid seems to involve the muscles, as they feel firm, hard, and brawny.

The patient remained in hospital until July 25th; no change occurred in the condition of the skin. He was discharged, and has since been lost sight of.

II. SCLERODERMA AND GRAVES' DISEASE.

Lewin and Heller make only one reference to this association, a case of Selme, in which the two affections coexisted. No details are given. This is Jeanselme's[1] case, quoted by Möbius[2] and others.

A woman, aged fifty-eight, who had from the twentieth year a tumor in front of the neck, which for seven or eight years had increased in size. There was slight exophthalmus, tremor, and tachycardia. For two years symptoms of scleroderma, beginning with local asphyxia of the fingers; sclerodactylism became marked, and pigmentation of the skin.

Möbius refers to the subject in the following paragraph: "Leube first observed scleroderma of the face and hands in a patient with Basedow's disease, a condition which diminished with the improvement in the exophthalmic goiter. Of late similar observations have been made by Eichhorst, Jeanselme, and others. According to Dittisheim the scleroderma in Basedow's disease is particularly common in Zurich. G. Singer believes that scleroderma usually occurs in connection with disease of the thyroid gland, which he has found affected in ordinary scleroderma." Leube[3] makes the somewhat remarkable statement, considering how rarely the condition has been described: "Frequently sclerema of the skin as a complication has been observed by me and by others." Grünfeld[4] reports an extremely interesting case in a woman, aged thirty-three, with well-developed Graves' disease of several years' duration. Extensive areas of scleroderma developed, but under the thyroid-gland treatment both the exophthalmic goiter and the scleroderma disappeared completely. Grünfeld also refers to a case reported by Kahler, the original of which I have not seen.

In the following case the scleroderma appeared shortly after the Graves' disease, and did not progress.

CASE V. *Advanced Stage of Graves' Disease—Remarkable Scleroderma of Both Legs.*—M. S., aged forty, of Emmittsburg, Md., consulted me March 23, 1897. The patient had had a bad attack of syphilis ten years ago, He was treated steadily for five years. He has been well since, but he now is apprehensive lest the remarkable trouble which has appeared in his legs should be associated with the syphilis. For two years he has had exophthalmic goiter, and has been under treatment by various physicians in different institutions.

[1] *Revue Neurologique*, 1894, 572.
[2] *Nothnagel's Handbuch*, Bd. xxii, s. 43.
[3] *Specielle Diagnose*, Bd. ii, 3te aufl, s. 287.
[4] *Weiner Med. Bl.*, 1896, 19.

Present Condition.—Patient is a fairly well-nourished man, brownish complexion, with all the characters of an aggravated type of Graves' disease. The exophthalmus is very pronounced. The thyroid is of medium size. There is marked visible pulsation, a thrill, and all the associated vascular phenomena. The apex beat of the heart is in the fifth and sixth interspaces, very marked thud of the first sound at the apex, and loud bruits in the apex region and over the body of the heart. The pulse-rate is variable, from 130 to 160.

The abdomen is full; the edge of the spleen can readily be felt. The liver is not enlarged. Knee-jerks are a little exaggerated. He has no joint troubles, and there is no special pigmentation of the trunk. The legs present a very remarkable appearance. He says that two years ago, shortly after the onset of the exophthalmus, he began to notice a change in the color of the skin of the legs. This has gradually increased and the skin has become swollen, infiltrated, and very hard. With the onset of this condition there was no special redness, no itching, nor any disturbance of sensation. Anteriorly it extends close to the tuberosities of the tibiæ; on the sides of the legs it does not reach so high, only to within about three inches of the head of the fibula on the right side, and a little higher on the left side. The form of distribution is quite symmetrical. Behind, it extends in an uneven border a little above the most prominent part of the calves. It shades insensibly into the normal skin. The color is a peculiar tan-brown. It is everywhere smooth, though there are in places little whitish elevations, particularly on the outer surfaces of the legs. One or two of these look like small fibroid nodules. They are very closely set over the skin, but only a few of them project beyond the surface. On palpation the affected areas feel leathery, firm, and hard. The skin can nowhere be picked up. The line of demarcation between the normal and the infiltrated skin is marked by a distinct ridge. A slight discoloration of the normal skin extends beyond the prominent part of this ridge. Below, the affection is limited accurately by a line corresponding to the tops of the boots. There is no coldness, and it does not pit on the deepest pressure.

May 21, 1897. I saw this patient again to-day. He has not been so well. The tachycardia and irritable state of the heart are evidently much worse. I have rarely seen such pulsation and heaving over the whole of the chest and anterior cervical region. There is the most marked pulsation of the veins of the backs of the hands, and the capillary pulse is readily seen. There is no essential change in the scleroderma. Subsequently this patient came into the private ward of the Johns Hopkins Hospital, and the persistent use of the ice-bag, with belladonna, digitalis, and aconite internally, relieved somewhat the irritable state of the heart. After leaving the hospital he became very much weaker, and died on August 8, 1897.

III. DIFFERENTIAL DIAGNOSIS.

(*a*) *From Brawny, Solid Edema.*—One meets occasionally in patients with long-standing renal or cardiac disease, with a solid edema

of the legs which is very similar to scleroderma; it is usually an induration following a chronic dropsy.

In the case of Joseph C., aged fifty-five (Hospital No. 5557), who had a chronic nephritis with swelling of the feet and legs for six or eight months, there was an extraordinary state of induration of the skin of the legs, extending as far as the middle of the thighs. There was no special change in color, nor was there great swelling, but the skin was exceedingly indurated, and so firm and hard that on the right leg no portion could be pinched up. On the left leg it only extended one-half the distance up the thigh. It interfered very much with the flexion and extension of the legs. When he was admitted to the hospital he had some swelling of the abdomen and of the genitalia. The patient thought that this condition of induration had come on within the year, and had followed the dropsy. There were no other areas of induration of the skin.

In another case, Robert C. P., aged fifty-five (Hospital No. 8654), admitted November 20, 1893, with chronic enterocolitis, an illness of about six-months' duration. Two months ago he noticed that the feet and ankles were swollen, and on several occasions since the swelling has extended to the thighs and genitalia. The swelling has gradually subsided, but the hardening of the skin of the legs has persisted. The note reads as follows:

"Patient looks thin; skin is desiccated and dry. There are a few ecchymoses about the wrist. The skin of the legs is curiously hidebound like scleroderma; there is no swelling; no edema; pits nowhere on pressure; it is impossible to pick up a portion of the skin anywhere on the legs or feet. To the touch it feels like a piece of firm vellum. On the inner side of the left leg is a healed ulcer." There were no other areas of sclerosis of the skin. He had signs of chronic nephritis, and he had very frequent movements from the bowels. He left the hospital unimproved December 11th.

(*b*) *From the So-called Scorbutic Sclerosis.*—This could rarely offer any serious difficulty in diagnosis. A case was admitted April 4, 1894, with purpura and the most remarkable brawny induration of the skin of the thighs and calves. The patient could not stand erect, owing to the semiflexed condition of the legs. The parchment-like immobility of the skin was due altogether to extensive subcutaneous hemorrhage, which also involved the muscles. The existence of purpura, the marked swelling, and the associated features make the diagnosis easy, but it is worth passing notice as one of the conditions in which the most extreme induration of the skin may be present.

(*c*) *From Myxedema.*—There is a stage of swelling or infiltration of the skin in scleroderma which may resemble Gull's disease very closely. It is greatly to be desired that those who have the opportunity of studying cases in this early period would give special attention to the local features, to the condition of the thyroid gland, and to the effects of thyroid feeding. In Case VI. the features were somewhat swollen, the eyelids puffy, and the forearms swollen, but the extreme vasomotor phenomena, the sclerosis of the fingers, the immobility, and the areas of necrosis made clear, it seemed to me, the diagnosis of scleroderma in the early stage.

(*d*) *From other Vasomotor and Trophic Affections.*—The early stages of scleroderma present features very liable to lead to error in diagnosis—the erythema, the infiltration, the pigmentation, the extreme cyanosis, and the superficial necroses may suggest Raynaud's disease, or even leprosy. I will first give the histories of two remarkable cases which illustrate these vasomotor phenomena in a very marked way.

CASE VI. *Onset with Vasomotor Changes in Arms and Legs; Gradually Scleroderma of the Fingers, with Areas of Necrosis on the Finger-tips; Beginning Scleroderma on Forearms, with Pigmentation.*—During the meeting of the American Medical Association in May, 1895, Dr. Davis of Saginaw brought to see me a Miss R. of Kansas, aged twenty. The case was shown at the Section on Neurology, and was subsequently very carefully reported by Dr. Herdman of Ann Arbor, in the "Transactions of the Michigan State Medical Society" for 1895. There was nothing of note in her family history, except perhaps that her mother died of consumption. She has five brothers and one sister, all living and well.

She was healthy and strong as a young girl. About the time of puberty she evidently suffered with chilblains, having cold hands and feet, and when the temperature was low the fingers got blue. For the past three or four years she has had marked vasomotor changes in the arms and legs. For more than a year she has noticed a curious stiffness in the face, and in the morning, particularly, it feels a little drawn. For more than a year the hands have been getting stiff, and the fingers have become flexed, so that she cannot put the hands together flat. The fingers have been very congested, and in the winter there were areas of necrosis on the pads of the terminal phalanges of all the fingers, and the knuckles have cracked. While her general health has not been much impaired, she has been nervous and miserable, and at times emotional.

Present Condition.—She is a healthy looking, well-nourished woman. The face is smooth, perhaps a trifle immobile. The movements of the muscles of the face are all normal. She says, however, that the upper lip in the morning feels a little drawn, and at times the face feels stiff and leathery. The skin looks smooth but not glossy, and the color is natural. To the touch

the cheeks and forehead feel normal, but comparing it with a healthy person one cannot pick up so small a piece. She noticed the stiffness and slight immobility a year ago. The eyelids are a little puffy and infiltrated. With the exception, perhaps, of this slight immobility and smoothness, there is nothing in the face which would attract the attention of an observer. She expresses it herself by saying that it feels all "drawn up."

On exposing the neck there is a transient erythema. The skin of the neck in front and behind feels a little stiff. The upper arms are well nourished, of good size, and nothing unusual is to be felt. The forearms are symmetrical, and look fuller than natural just above the wrists. There are areas of pigmentation at the flexures of the elbows, and on the anterior surfaces of both arms the skin is glossy. About the central part of the forearms the skin is leathery, parchment-like, and cannot be picked up from the subjacent tissues. The hands and fingers look full and large. They are congested, reddish, the skin shiny. She makes a fist with difficulty, and the knuckles become very anemic. The fingers are a little flexed, and owing to this she cannot put the hands flat together. The skin of the hands and fingers is everywhere firm, resistant, glossy, and cracked over the convexities of the first phalangeal joints. The nails are well formed, except on the left thumb and both index-fingers, where they are small, deformed, and incurved. The pads of all the fingers and of the thumbs are scarred from suppuration and necrotic changes. In cold weather they crack open and sores form. The palms of the hands are moist and very firm and rigid. The tactile, painful, and thermic sensations seem perfect. There is no enlargement of the bones.

The feet are congested, the toes quite purple, looking in a condition of extreme local asphyxia. This, she says, is her constant state when she is up and about. There is a large amount of fat on the legs. The skin does not feel drawn, and there is no diffuse sclerosis. There are no areas of anesthesia. The skin of the abdomen is not affected. Her general condition appears good, and the various functions seem normally performed.

Throughout the year the patient was under treatment with galvanism at her home in Michigan, and about December 1, 1895, she began to use the thyroid extract. Dr. Davis writes on December 7th: "Her feet and hands are so cold all the time that she often sits with warm mits on her hands, and her feet on a hot gridle. The fingers have been sore ever since early in the fall; three or four of them are tied up all the time, and before one is well another begins to be painful and sore."

In March, 1896, Dr. Davis reported that there seemed to be a great deal of improvement under the use of the thyroid extract. The fingers healed, and she seemed altogether better. He thought, too, toward the end of March that there seemed to be some improvement in the hardened indurated regions of the skin.

She took the thyroid extract from November, 1895, to June, 1896.

I heard from this patient on September 12, 1897. She appears to be very much better. Her feet and hands have improved greatly. She has had no

soreness of fingers for more than a year. Her general health is good. She has not taken the thyroid extract since December, 1896, and she attributes her improvement to a general tonic course of treatment, and to the fact that she lives a very much quiter life, taking better care of herself.

CASE VII. *Scleroderma of the Hands and Fingers, and to a Slight Extent of the Cheeks; Tachycardia; Extraordinary Cyanosis of the Skin of the Legs; Subcutaneous Fibroid Nodules.*—Mr. X. of ———, Ga., aged forty-nine, was seen June 15, 1896, with Dr. Charlton, and admitted to the hospital June 17th, complaining of stiffness of the hands and rapid action of the heart.

Family History.—His father died at seventy-three; his mother is living and well; brothers and sisters are all strong and well. There are, so far as he knows, no special diseases in his family.

Personal History.—He has been a very healthy man. He had malaria when in the army, but for the past twenty-five years has scarcely lost a day from sickness. He has been a free liver, eating and drinking carelessly; he has never been in the habit of going on sprees.

His present illness dates from October, 1895, when he had what was supposed to be an attack of influenza. He had rheumatic pains for several months, chiefly in the muscles, usually shooting in character. He was weak and prostrated. About November he had an attack of acute inflammation of the right foot and ankle, which persisted for several weeks, and was severe enough to confine him to bed, and only yielded under the use of colchicum and iodid of potassium. He recovered from this very slowly, and was very prostrated and weak.

In the latter part of January he went to Florida, and the rheumatic pains gradually disappeared, but his general condition of ill-health did not seem to be much improved. The foot became easily swollen and very much congested. He noticed the stiffness of the hands coming on gradually through the autumn, and the hardness and coldness have increased very much since the first of January. He had occasionally pains in the hands, but latterly it has been chiefly a little pricking sensation in the pads of the fingers. The pains in the legs have all disappeared. The doctor says that the rapid action of the heart has been quite marked, and he has at times been very short of breath.

Present Condition.—The patient is a well-preserved man; expression of face natural; the normal folds and wrinkles are present. On the right side of the forehead there is a nodular induration, the size of a small cherry, which he says was present as a small spot as a boy, when he received a blow with a piece of brick. It has grown very much since his illness, and at present feels like a firm, subcutaneous fibroid nodule adherent to the periosteum. There are no tophi in the ears. The movements of the face are perfect. He says, however, that as he moves the muscles there is a sense of stiffness and effort, particularly about the cheeks. The skin everywhere feels normal, except just above the nasolabial folds, where it is parchment-like and a little smooth. There are no special changes in the hair.

On exposing the neck and chest the skin at once becomes very hyperemic. There is no trace of induration of the skin.

The upper arms are not involved; the movements are perfect. The skin of both arms from about the middle of the forearm is hidebound and cannot be picked up from the subjacent tissues. There is no pigmentation, and no changes in color.

The hands and fingers are very much affected. They are cold, moist, and look congested. The skin of the back of the hand is picked up with difficulty, and in a very large fold. The fingers are firm, hard, and entirely hidebound. They are cold, and as he expresses it, "feel just like sticks." He cannot make a fist; the terminal phalanges cannot be flexed at all. The proximal phalangeal joints can be bent nearly to a right angle. The fingers are held constantly semiflexed. The pads are very firm, the skin red and shiny; there is no loss of substance. The palms of the hands are hard and leathery.

Legs.—He walks and stands well; the reflexes are normal. The legs feel sometimes a little heavy and full. There is no involvement of the skin of any part. The ankles look a little puffy, and both feet are marked in several places with the boots. On deep pressure there is slight pitting half-way up the legs. After standing up to undress and dress himself the skin of the legs and feet presented the most remarkable appearance. They became congested, purple, and cold, nearly half-way up the thighs. There was evidently very great venous stasis and the finger-mark was filled up very slowly. This extraordinary condition, the doctor says, has been present ever since the autumn, and is especially noticeable in the morning after he gets up. There are no trophic changes in the skin; the feet are moist, and he sweats naturally. The ankle-joints are freely movable. The big-toe joints are neither swollen nor tender.

In the hospital, after having been in bed for thirty-six hours, the change in the condition of the legs is remarkable. There is no trace of redness, and the puffiness has disappeared completely. The pulse in the erect posture was 138; after twenty-four hours rest in bed it was 90. The arteries are not sclerotic. The apex beat is in fifth interspace, area of transverse dulness increased, a soft systolic murmur at the apex, probably due to the rapid action of the heart. At the base the sounds are clear.

Urine.—Yellow; opaque; heavy white sediment; faintly acid; amorphous phosphates; no casts; 1010; no albumin; no sugar.

September 7, 1896. The fingers look scarcely so purplish as they did, and I think are scarcely so cold. Otherwise there is no essential change. The nails are all heavily ridged horizontally, and the ridges are beaded. The erythema extends up the arms; no special change in the face. He complains somewhat of a little numbness on the left side of the mouth, and on the upper and lower lips, and along the left cheek as far as the lobe of the ear. The nasolabial fold is a little stiff, as it was at the first examination. There is no special change in the skin of the trunk. The feet are

very livid and cold; skin about the ankles and feet feels a little indurated. Certainly, as he sits down there is less congestion about the legs.

He has had a good summer. The pulse-rate has been from 84 to 108; average of 95 or 96. There has been no palpitation of the heart, except for a week when he stopped the digitalis mixture. He took the thyroid extract faithfully until about a month ago. He is stronger, able to get about better, and the color of his face is better. His present weight is 138 pounds, the same as when he came to Baltimore. The weight fell to 131 pounds, but has gained again.

The patient heard from on September 12, 1897. The condition has remained stationary; probably slight improvement, since he is now able to attend to his business.

December 21, 1897. I saw this patient to-day. He has been taking almost uninterruptedly the thyroid extract, and the digitalis; of the latter, 10 minims three times a day. He thinks in many ways he is much better, able to do more, can walk four or five miles, and has been able to attend to his business actively. The remarkable vasomotor changes in the skin of the legs is very much less marked, though he still when he stands up has great congestion and lividity of the feet. The tachycardia has diminished. The pulse-rate is rarely now above 90, though to-day on first examination it was 120. The scleroderma has certainly made no progress in extent. It is still confined to the hands and to a small extent to the face. In the hands the fingers are harder, but there have been no spots of necrosis, and he is still able to flex the fingers so that they can touch the palm of the hand. His face looks much better and has lost the puffy infiltrated appearance. Only about the cheeks there is very positive induration. He says that the lobe of the left ear at times feels a little stiff. He complains, too, of peculiar sensations about the lips, and a tingling, particularly if he takes anything very hot to drink. As the thyroid extract had been given a full trial, it was stopped, and he was ordered salol, grs. xv, t. i. d. (according to Phillipson's[1] directions), a drug which seems to have been very successful in his hands.

Case VI. was shown in the Neurological Section of the American Medical Association at Baltimore, and no unanimity was reached in the diagnosis. It is evident, too, on reading Dr. Herdman's report, that when the patient was under his care the nature was not quite clear, though he inclined to regard it as an anomalous instance of scleroderma.

Case VII. presented a remarkable series of vascular changes, erythema, extreme vasomotor paresis, and tachycardia. I never remember to have seen such extraordinary cyanosis as developed within a few minutes in the legs as he stood up. It was almost as if one could see the blood filling the vessels, and the engorgement became more and more pronounced until the legs to the middle of the

[1] *Deutsche med. Wochenschrift*, August 12, 1897.

thighs were plum-colored. The tachycardia is an unusual feature, not mentioned by Lewin and Heller. It has been persistent. The subcutaneous fibroid nodules met with in this case have been described by Hutchinson and others in this disease. The erythema, with swelling of the skin and pigmentation, not uncommon early symptoms of scleroderma, may lead to the suspicion of leprosy. Dr. Boyce of Kelowna, B. C., brought a remarkable case to the Montreal meeting of the British Medical Association. The members of the Dermatological Section did not agree upon the diagnosis. I saw the case subsequently, and the erythema, the infiltrated areas, and the pigmentation seemed to me suggestive of beginning scleroderma. Many of the members of the section thought the case was one of macular leprosy, a point in favor of which was the swollen condition of the ulnar nerves, which, so far as I can ascertain, has not been described in scleroderma. The patient improved somewhat on the thyroid extract, but Dr. Boyce wrote that he died suddenly ten days after his return to his home. To within a week of his death he was taking 5 grains of the thyroid-gland extract three times a day. Sudden death, rare in early leprosy, is not unknown in scleroderma. A case of Dinkler's and one of Willrich's died without recognizable clinical or anatomical cause.

IV. SCLERODERMA AND ADDISON'S DISEASE.

Increase in the pigment of the skin is a very striking feature in scleroderma. It was present in a marked degree in Case VIII. It occurred in 144 of the 508 cases collected by Lewin and Heller. As a rule, slight in degree, and not widespread, occasionally when deep and general it raises the suggestion of Addison's disease. Lewin and Heller speak of at least four cases in which the diffuse scleroderma was regarded as a complication of Addison's disease. As one of the cases in my series presented an extraordinary grade of pigmentation, and as I have looked upon the increased pigmentation as only an exaggeration of a not uncommon trophic change, it may be well to see in the other cases how far the diagnosis of Addison's disease was justified. Fereol's case (No. 119 in Lewin and Heller's series), a man aged forty-three, presented extensive scleroderma, brown color of skin on shoulders, trunk, and face. No mention is made of special cardiac weakness or gastric symptoms. I see no reason whatever to regard this as a case of Addison's disease, and Fereol himself thought it scleroderma with vitiligo. Rossbach's case (No. 8) was in a woman aged sixty-two, with advanced diffuse scleroderma; the skin of face, neck, and hands gradually became dark; the pigmentation extended.

The patient died anasarcous. There is nothing in the abstract, as given by Lewin and Heller, or in the original, to suggest Addison's disease, and the only note on the *post-mortem* is "extreme anemia of the internal organs; hypertrophy of the liver."

Willrich's patient, aged sixty-two (No. 359, Lewin and Heller), had scleroderma of the right hand and arm, with pigmentation of the back of the hand and forearm, face, and neck; later, sclerosis of the thighs; great anemia. *Post-mortem*, no changes were found in the adrenals or in the solar plexus. Here, too, there is nothing whatever to suggest Addison's disease other than the pigmentation. Another case, Leloir's, is said to have *suggested* Addison's disease. In none of these cases was the pigmentation associated with disease of the suprarenal capsules. A more likely case is reported by Schultz,[1] aged nineteen, with sclerosis of the arms and legs, and much muscular atrophy, pigmentation of the face and neck. The patient became extremely feeble, had abscesses and bed-sores, and died somewhat suddenly within four months of the onset of the illness. The right suprarenal was normal; the left was moderately increased in size, adherent to adjacent parts, and presented a few small grayish nodules. The nature of the change in this capsule is not very clear; the cells were swollen, and there were groups of fusiform cells between the glandular columns. I do not think it is possible to say that this patient had Addison's disease; the symptoms certainly do not suggest it, and the state of the left adrenal was too indefinite to allow of any conclusions.

In the following case a maximum grade of pigmentation was present, as illustrated in the colored drawing, for which I am indebted to Miss A. Blackwell. Except the bronzing there was no feature of Addison's disease. There has been no irritability of the stomach, and no extreme prostration, certainly no debility out of proportion to the general disease. I believe that in this, as in the cases above referred to, the deepening of the color is only part of a trophic change in the scleroderma, and has nothing to do with true Addison's disease.

CASE VIII. *Diffuse Scleroderma; Intense and General Pigmentation with Patches of Leucoderma; Swelling of the Inguinal Glands; Progressive Advance in the Disease.*—S. A. B., aged thirty-nine, a timber inspector, Virginia, was admitted to Ward E of the Johns Hopkins Hospital, May 21, 1896, complaining of weakness, bronzing of the skin, and inability to use his hands.

Family History.—His father died aged thirty-six, cause doubtful; his

[1] *Neurologisches Centralblatt*, 1889.

mother died in labor; two brothers died of diphtheria; one brother and one sister are living and well.

Personal History.—He has had most of the usual diseases of childhood. Three years ago he had rheumatic pains in the joints, but he was not laid up in bed. He had an attack of jaundice two years ago, which lasted several days. He was formerly a heavy drinker, but for some years past he has been more moderate. He had gonorrhea once; has never had syphilis. As a rule, he has enjoyed very good health, and has been able to work hard. His work has been out of doors, with only an average amount of exposure.

Present Illness.—About fifteen months ago he began to feel stiffness in the fingers of both hands, and a short time later his feet and hands became swollen. His face was also swollen for a month or two. He said that it was quite moderate, but he was sure that it was present, and he thinks it followed the feeling of stiffness in the hands. About four months after the first symptoms he noticed that his hands and fingers were becoming very dark in color, The trouble has progressed steadily, and within the past six months his legs have become so stiff that he walks with great difficulty, and the hands have become so much involved that he has almost lost power in them. He has noticed, too, a progressive involvement of the face, an uneasy sensation of stiffness on attempting to move the muscles, and lately an inability to open the mouth wide. For some months past there has been an increasing pigmentation of the skin of the face, and of the chest and abdomen.

His general health has suffered very much. He has lost in weight, and the appetite and digestion are much impaired, but he has had no vomiting.

Present Condition.—The patient is a small man, weighing only 102 pounds. Everywhere there is moderate emaciation. His hair and beard are dark; the eyes are gray; features look small and drawn. The skin of the cheeks and forehead is smooth and without wrinkles. The nose and ears look natural. The skin of the forehead is a little glossy, but he can wrinkle it voluntarily. He can retract the upper lip, and move voluntarily all the muscles of the face, but he says the movements are very stiff. The mouth cannot be opened to more than half the normal extent. The skin of the face and neck is very dark, suggestive at the first glance of Addison's disease. On close inspection of the face it is seen to be not uniform but patchy, particularly about the cheeks. The pigmentation is more intense on the neck than on the face. The skin of the forehead feels thin; it is somewhat hidebound, and is with difficulty picked up. Over the cheeks it feels a little thick and brawny. There are no changes in the skin of the ears or of the scalp. Under the jaws it is thin and readily pinched, but on the front of the neck, in the cervical triangles, over the sternum and clavicles, and over the lower part of the back of the neck it is indurated and parchment-like. In these situations it is seen to have a drawn, tight appearance, which is well shown in the photograph. (Fig. 3.) The sternomastoid muscles and the clavicles stand out very prominently. Over the thorax the skin is deeply pigmented, in places quite patchy, and there are

FIG. 3.

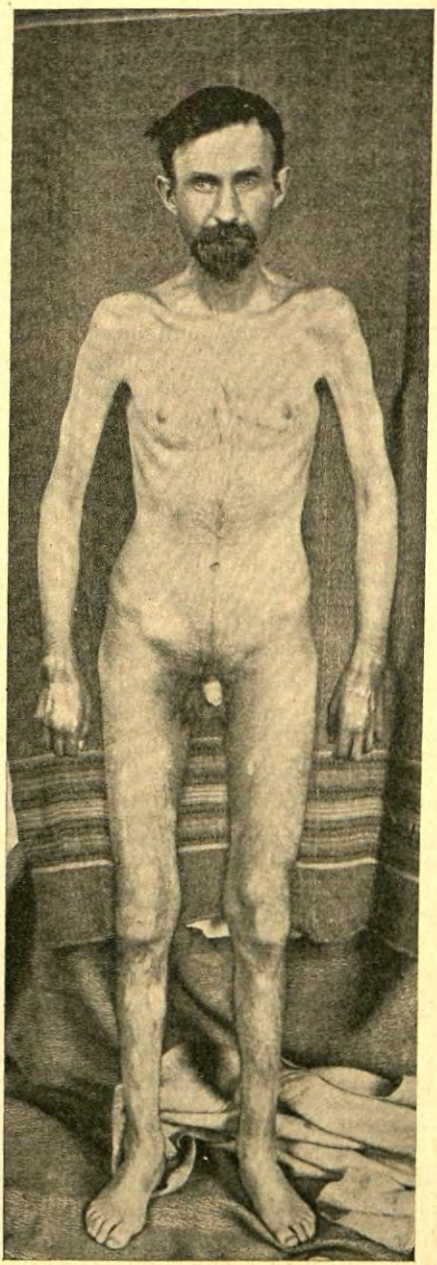

lines in which it is very deep. It is absent over the pectoral fold, and is not nearly so marked in the axilla; the areolæ of the nipples are not very dark. It is very intense on the skin of the back, except the supraspinous fossæ. The skin over the upper part of the chest is quite hidebound. It is very much less marked in the axillary region. Over the back the skin is very leathery and dense. When he attempts to move the arms they cannot be raised above the level of the shoulders, and the motion backward is very much restricted, owing to the induration of the skin over the shoulders and chest.

The skin of the abdomen presents a very intense pigmentation. Toward the pubes and in the iliac fossæ it is as dark as a mulatto, with scattered areas of leucoderma, which give it a peculiar mottled appearance.

There are bunches of enlarged lymph-glands both above and below Poupart's ligament on both sides. These are well shown in the photograph. There are no other glandular enlargements in the body. The arms are thin, musculature feeble; the motion is much limited. They cannot be moved backward to any extent, and he cannot raise the elbows level with the shoulders. The skin feels everywhere stiffened, less in the upper than the lower arms, in which it can scarcely anywhere be picked up in a fold. There is no difference in the two arms. The arms can be flexed and extended. The pigmentation of the skin is moderate on the upper arms, and deepens greatly toward the wrist.

Hands.—Right: Pigmentation of the dorsum is extreme. Over the first, second, and third metacarpal bones there is a large patch of leucoderma. The skin of the hands is of a deep mahogany brown. The patch of leucoderma has in it many spots of pigmentation, which are shown in the accompanying plate. Flexion and extension of the wrists are much restricted, owing to the induration of the skin. The fingers are in a position of semiflexion and cannot be extended; movement at the metacarpal joints is very limited. The second phalanges cannot be extended upon the first, nor the third upon the second. The position of the hand is well represented in the photograph and in the colored plate, which also shows the deep pigmentation. There is a great deal of hair about the wrists, more than on the arms, but this he says was always present.

The left hand presented the same appearance, except there were fewer patches of pigmentation. There were no losses of substance on the pads of the fingers; the nails were natural looking; there was a small festering sore on the first phalangeal joint of the middle finger of the left hand. The fingers and hands feel cold and hard as though modeled in wax. The skin is everywhere closely united to the subjacent tissues, and cannot be folded or pinched. The palmar surfaces are not affected—not pigmented. The disability in the hands is extreme, and though it does not hurt him to make any movements, yet he can only just approximate the thumb to the fingers, and has great difficulty in feeding and clothing himself.

Legs.—The pigmentation is very marked on the thighs and is mottled on the inner aspect. The pigmentation is much less on the legs; less, in fact, than on any other part of the body. The legs cannot be fully flexed on the thighs—can scarcely be brought to a right angle. The movements in the ankles are fairly good. The skin of the thighs is uniformly involved, feels stiff and leathery, not more marked in one place than in another. When the legs are flexed there is a sort of creaking in the extensor tendons. Over the legs and feet the skin is very hidebound and can nowhere be folded. The knee-jerk is present.

Sensation.—A touch or a pin-prick is everywhere felt. Heat and cold are readily distinguished. The skin is dry, but he says he sweats in the warm weather and the palms of the hands are now moist. The mucous membranes are normal and present no pigmentation. There is no change whatever in the condition of the urine; sp. gr., 1025; acid reaction, no albumin, no casts.

Examination of the heart and lungs and abdominal viscera was negative. The temperature was normal. Pulse from ninety to ninety-five per minute; rather small, but of good tension.

The patient remained in hospital until June 2d. He was given thyroid extract on May 23d, grains iii t.i.d.

November 12, 1896. A note from this patient's brother, who is a physician, stated that he has taken the thyroid extract at intervals ever since he was in the hospital. At first he thought it benefited him, but of late he

has been slowly but steadily declining; the joints are stiffer and the skin very much harder.

Patient heard from September 21, 1897. He stated that he was in very much the same condition, so far as his general health was concerned. The joints were stiffer and his hands were nearly closed, and the fingers very badly drawn in. The discoloration he reports to be the same. The thyroid extract has not done him any good.

V. THE THYROID TREATMENT OF SCLERODERMA.

Singer[1] found the right lobe of the thyroid gland much reduced in size in a typical case of diffuse scleroderma, and suggested that the disease was due to dysthyreosis in consequence of the chronic fibroid changes in the gland. By far the most important contribution to the question has been made quite recently by Hektoen [2] In a woman aged fifty-one, with diffuse scleroderma, the thyroid gland was found to be small and fibrous, weighing only fourteen grams (average about twenty-two). It was the seat of extensive fibrous changes with atrophy and destruction of the glandular portion. The iodin separated was only 2.94 milligrams, only one-third the amount contained in the normal gland. I know of no other cases in which the thyroid has been found diseased. Hektoen concludes: "Now, if athyreosis can produce such changes there can be no inherent reason why dysthyreosis, due to various causes, may not lead to scleroderma. In this case it lies temptingly near to assume that the endarteritis of the thyroidal vessels may have been the essential cause of the changes in the thyroid and, in accordance with the suggestions already made, indirectly of the scleroderma. Arteriosclerosis might, it would seem, lead to parenchymatous atrophy and fibrous growth in the thyroid as well as in other organs. Viewed from this point, the arteriosclerosis would seem to play an indirect but essential part in the genesis of the diffuse scleroderma of the old rather than the direct rôle advocated by Dinkler and others. The causes that may disturb the functions of the thyroid and the results thereof are various, and it seems warranted to suggest that the relations of arteriosclerosis, dysthyreosis, and scleroderma merit further study."

Marsh[3] of Troy, N. Y., has reported a case of scleroderma in a child aged two, which followed diphtheria. The condition was quite extensive. Marked improvement followed the use of the extract in grain doses. Dr. Marsh writes (December 29, 1897) that the child has recovered completely, and now shows no trace of the disease.

[1] *Berliner Klin. Wochenschrift*, 1895, No. 11.
[2] *Journal of the American Medical Association*, June 26, 1897.
[3] *Medical News*, vol. lxvi.

Dreschfeld[1] used the thyroid extract in two cases of diffuse scleroderma. In one, there was improvement at first, and the skin became softer, and when the medicine was discontinued she noticed an increase in the stiffness. There was no ultimate benefit. In the second case the thyroid gland extract did not seem to do any good.

At the New York Dermatological Society on September 25, 1894, Dr. Lustgarten[2] referred to a case of generalized scleroderma cured by the use of the thyroid extract. I can find no full report of this case.

The most successful case in an adult is one reported by Grünfeld,[3] already referred to under the section on "Scleroderma and Graves' Disease." The scleroderma disappeared entirely after the use of the thyroid-gland extract. No atrophy was left in the affected areas. Four cases are referred to in Lewin and Heller's monograph, all unsuccessful.

Six of the cases here reported took thyroid-gland extract for periods ranging from ten days to nineteen months. In Case III. the patient only took the thyroid extract for a few weeks, and her friends stated that under its use she improved slightly. She died of an acute gastro-intestinal trouble, but I could get no information as to whether this had any relation to the use of the thyroid extract, or even whether she was taking it at the time. Case VI. took the thyroid extract from November, 1895, to June, 1896, in doses of from 2 to 5 grains three times a day. She improved, had no soreness of the fingers, and the general health was better, but she attributed her improvement more to general tonics than to the thyroid extract. This patient was in the early stages of the disease, and she certainly took the thyroid extract long enough to determine whether or not it had a curative action. In Case VIII. the patient was in an advanced stage of the disease. He took the thyroid extract in from 3- to 5-grain doses three times a day from May 23, 1896, until about the middle of November, 1897. He omitted it for a few days at intervals. According to the statement of his brother, who is a physician, it did not seem to do him the slightest good. In Case II. the extract was used almost continuously for nineteen months, most of the time in 5-grain doses. While he thinks that he is better, there is no obvious change. The disease has not progressed actively. Case VII. is very interesting, as the patient was in an earlier condition showing very marked vasomotor changes. He took the thy-

[1] *Medical Chronicle*, January, 1897.

[2] JOURNAL OF CUTANEOUS AND GENITO-URINARY DISEASES, vol. xiii.

[3] *Loc. cit.*

roid extract from the time of his admission to the hospital, June 17, 1896 to December 21, 1897, when I last saw him. As a rule he took two 5-grain tablets daily, occasionally reducing it to one. Though the condition in his hands has not improved, yet in the eighteen months the disease has certainly not progressed. His general health is very much better, and the vasomotor changes are not so evident.

One interesting point is brought out, particularly by these last two cases; namely, the harmlessness of the protracted use of the thyroid extract. In Case VII., though the patient had tachycardia, he took the remedy without any ill effects. In Case II. the patient gained in weight under its use. The thyroid extract has certainly no specific action in scleroderma, as it has in myxedema. In no case did the skin of the affected regions become softer or regain its natural appearance.

In two of my cases the disease did not progress under its use, but this is the best that can be gathered from my own experience. Of course it might be said that it was only in the early stages that good results could be expected, but two, at least, of my cases had a fair trial, while the affected parts were still in the stage of infiltration and erythema.

In Dr. Marsh's patient—one of the few in which a permanent cure has followed the use of the thyroid extract—the question may be raised whether the case was one of diffuse scleroderma, or whether it was not one of acute sclerema—of the same nature as sclerema neonatorum, following diphtheria. The whole process was very acute, extending from the first inception to complete cure, over a period of only four months.

Altogether, my personal experience and the results, as recorded in the literature, do not favor the treatment of the disease by the thyroid-gland extract. It may be tried without harm, and should it fail, frictions, and salicin preparations should be used.